

UHID	: P251210003	Appointment Date	: 10/12/2025 8:30:00 AM
Name	: REBECCA ODARQUAYE	Contact No.	: 0506287979
Age/Sex	: 36YRS/Female	Panel	: CASH
Doctor Name	: Prof. Benjamin Sarkodie (INTERVENTIONAL RADIOLOGIST)		
Address	: Greater Accra, Ghana		



TransFemoral Cerebral Digital Subtraction Angiogram (TFC-DSA)

HISTORY:

SAH

REPORT

Procedure: Cerebral Angiogram

Operators: Prof. Benjamin D. Sarkodie

TECHNIQUE:

Through a 6F sheath inserted via a right common femoral artery puncture, a 5F Headhunter catheter was introduced and manipulated into the aortic arch under fluoroscopic guidance. Selective right and left internal carotid as well as left vertebral arteriograms were obtained.

The sheath was removed at the end of the procedure and hemostasis was secured with manual compression.

Contrast: Iopamirol 300 x 100cc

Complications: None

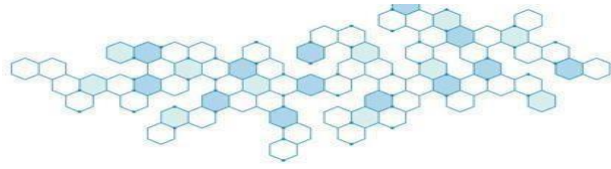
Medications: 1% lignocaine 10mls

FINDINGS:

1. Left ICA Bifurcation / terminus ICA Aneurysm measuring 4.3 x 1.7mm (Neck 2mm)
2. Left Supraclinoid ICA Aneurysm measuring 2.5 x 2.4mm (Neck 2mm)

Recommendation:

Endovascular coiling Suggested.



EURACARE SPRING

A MULTI-SPECIALIST HOSPITAL

Euracare Spring.

H/N. 3 West Trasacco, East Legon, Accra, Ghana | P.O. Box 45, Accra, GA/R

Tel: +233 (0) 302 739 390 | Fax: +233 (0) 302 739 396 | E-mail: info@euracare.com.gh | Website: www.euracarehealth.com